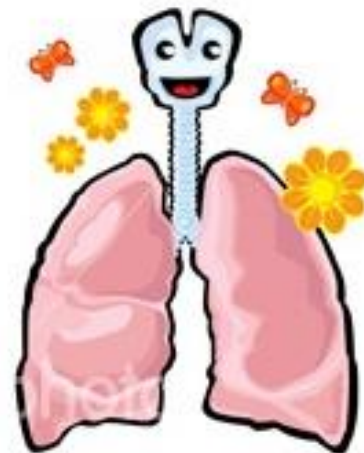
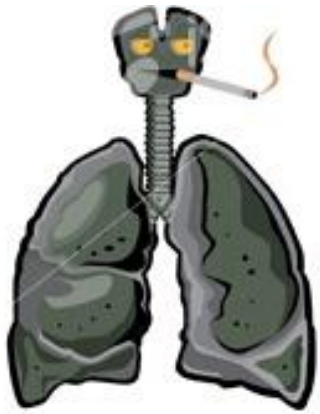

Respiratoir Falen en de **Bedreigde** Lucht...Weg

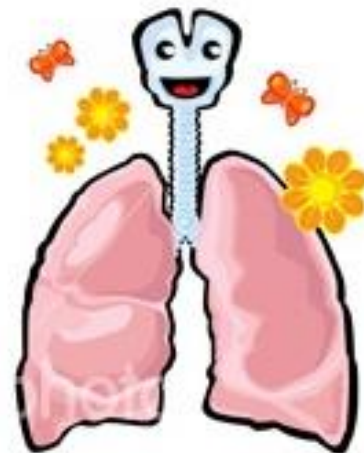
Patrick Van de Voorde
adjunct-kliniekhoofd
Intensieve Zorgen en Urgenties
Pediatrie, UZ Gent

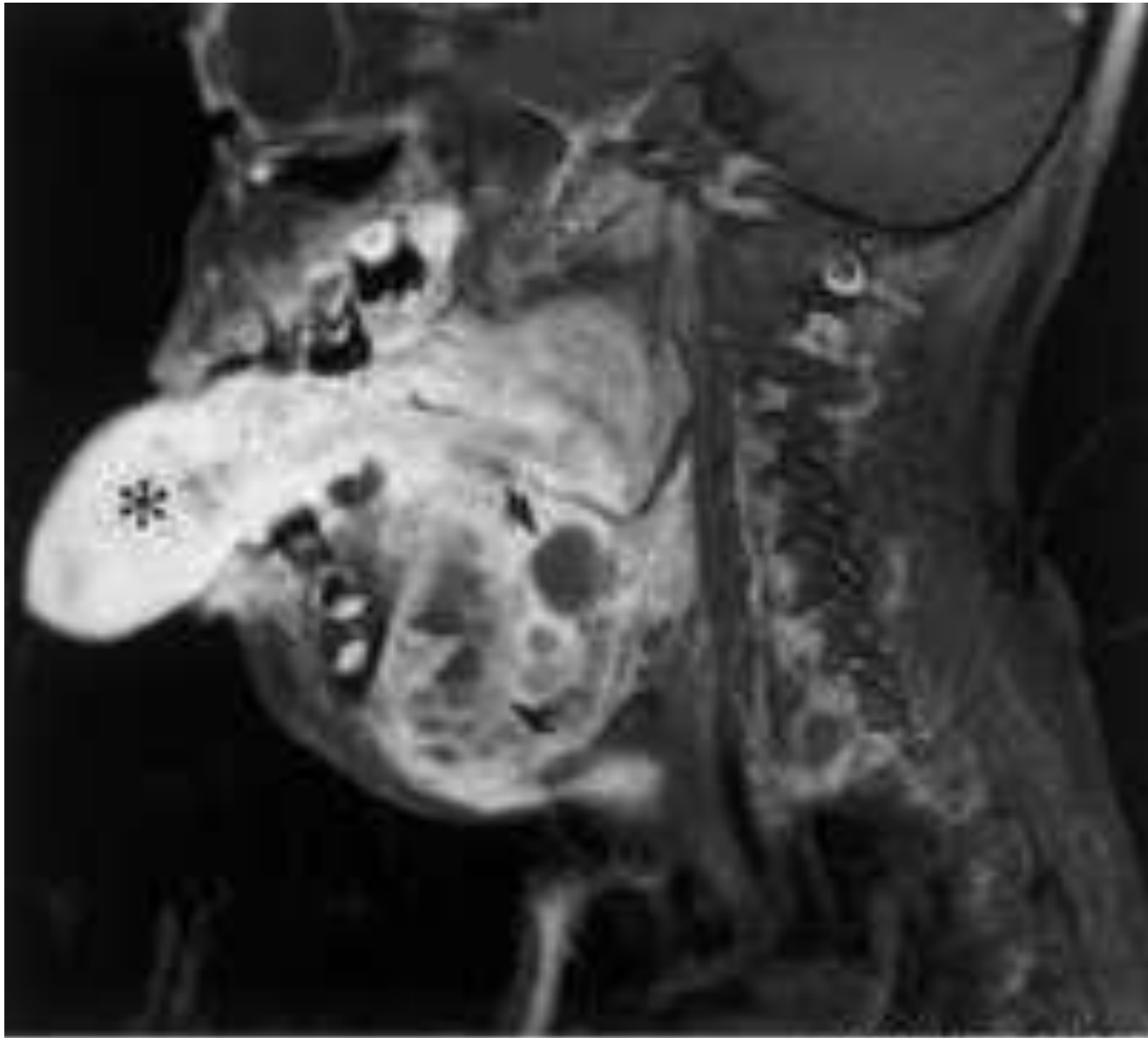




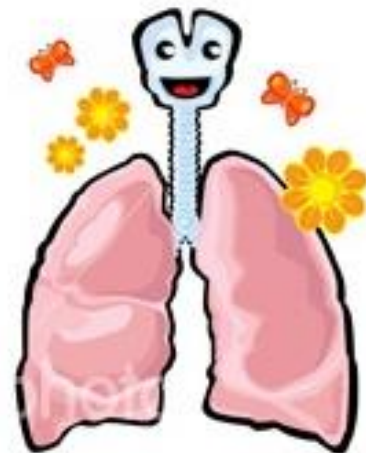
LIESJE IS ... jaar en...

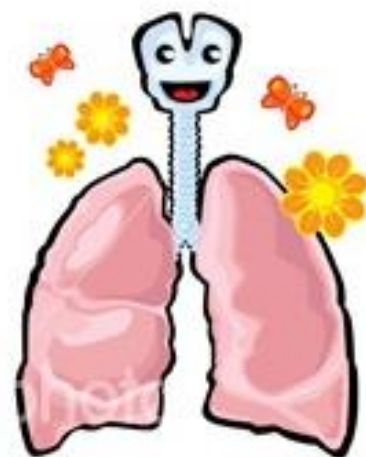
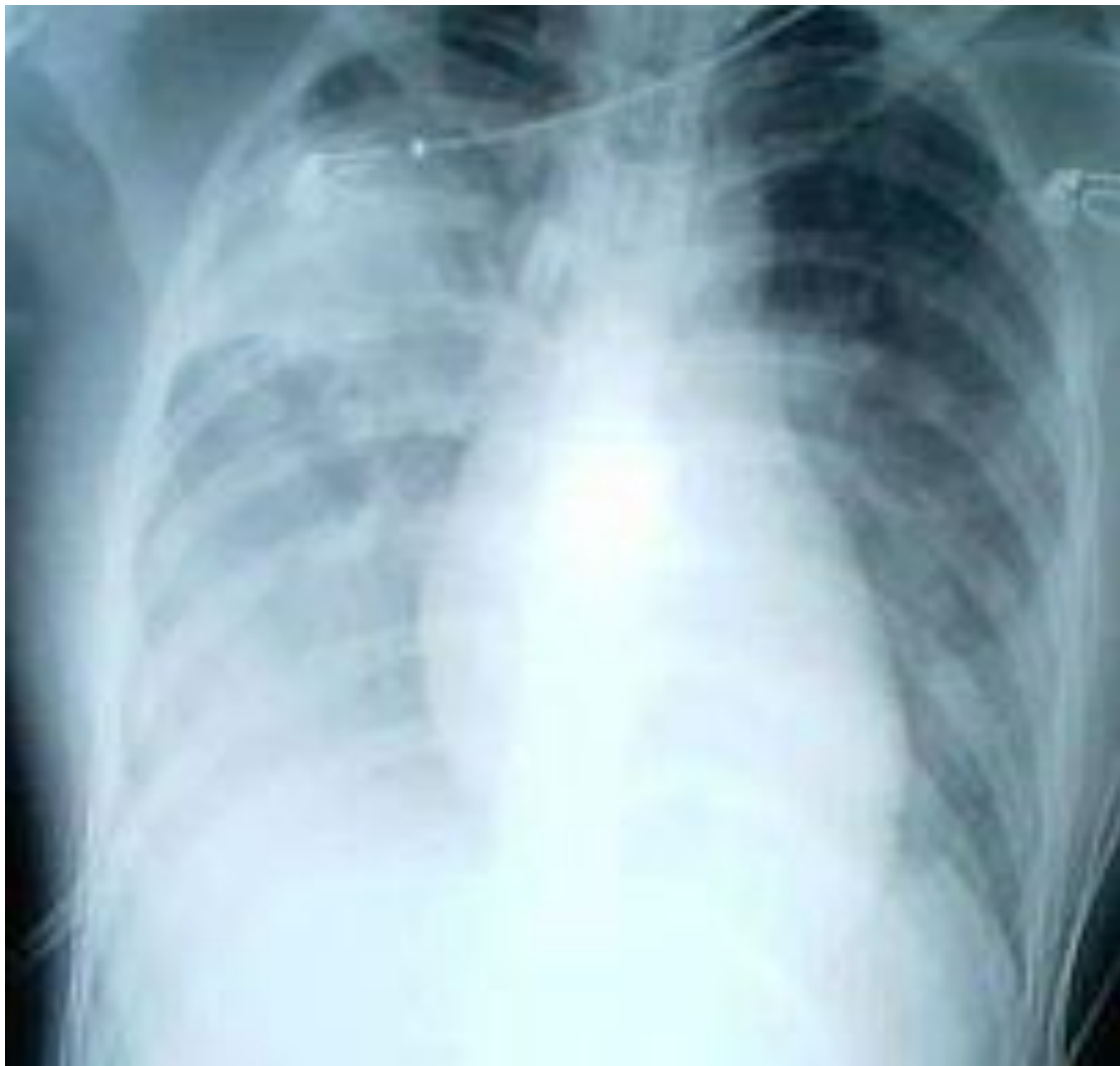EEN BEETJE ZIEKJES....

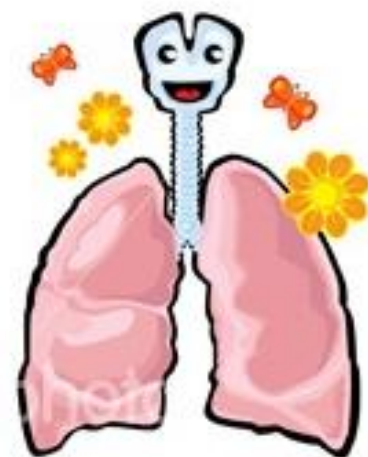




© 2008 Elsevier Inc.

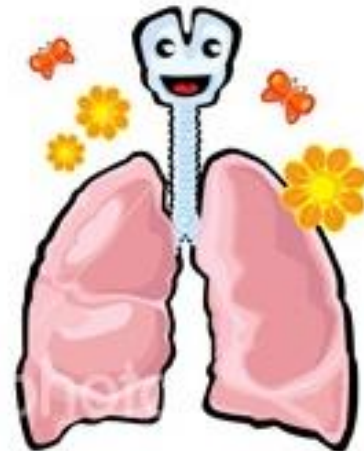






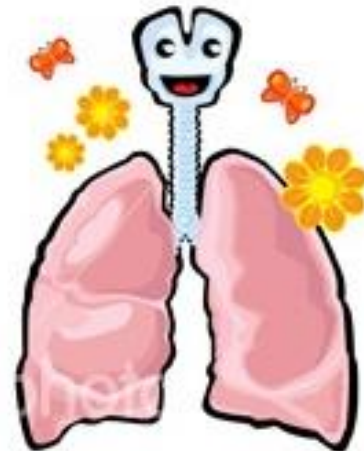
De aanpak van elke urgentie begint bij...

ABCD

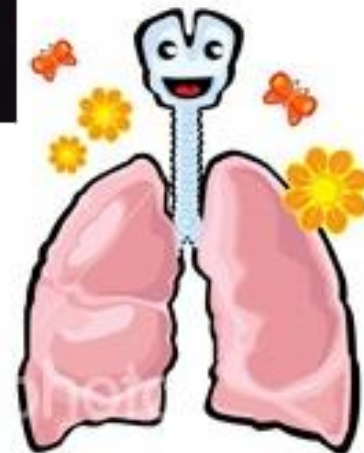
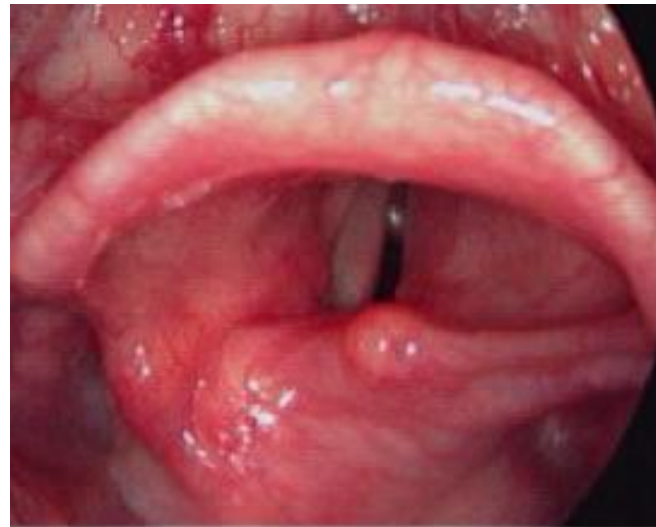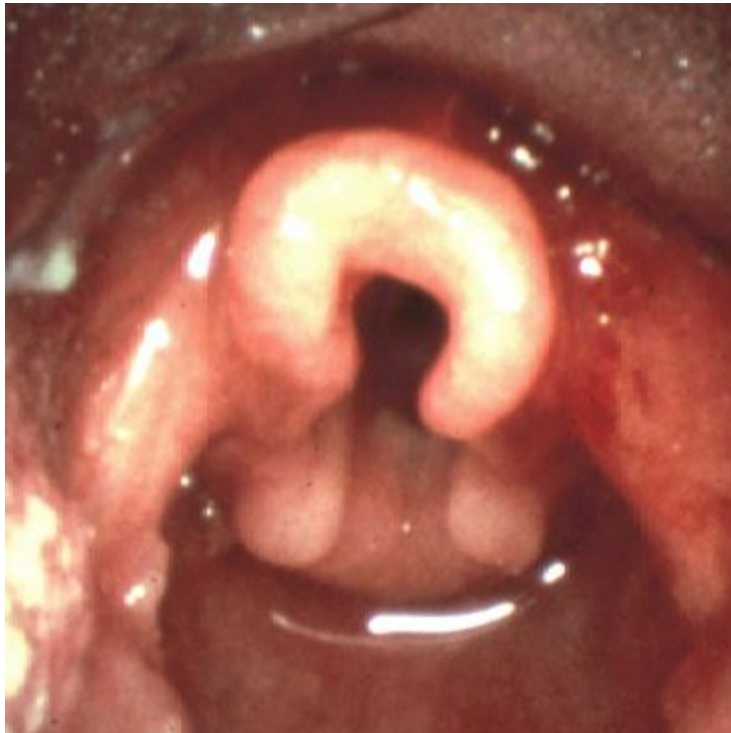


A van Luchtweg: bij kinderen...


- Epiglottis floppy, rigid U vorm, steekt langer uit naar anterior
- Cephalic (C1-C4) & ant. Larynx, stembanden in hoek tov farynx
 - Eerste levensmaanden obligaat neusAH!!
- Nauwste punt = cricoidring (trechter <8j)
- Prominente arytenoiden, commissura ant.
- Smal aangezicht, Nauwe mandibula
- grote TONG
- Korte en nauwere Trachea
- Groot achterhoofd!



Epiglottitis child vs. adult



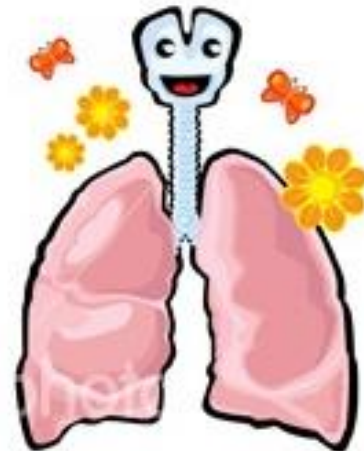
Nauwere luchtweg diameter en Poiseuille



- $R = 8 L \eta / \pi r^4$
 - R = LW Weerstand
 - L = lengte
 - r = radius
 - η = viscositeit gas

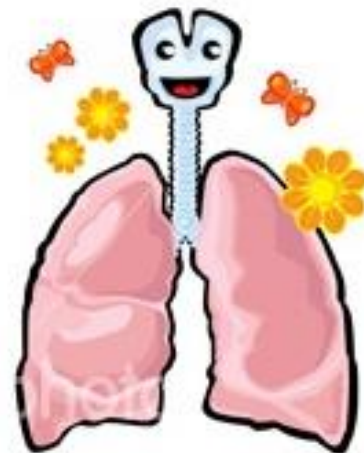
Met name sterke toename W
bij beperkte stijging radius

Met name 0.5mm oedeem meer impact
op nauwe ped. dan op volwassen LW



Fysiologische Verschillen bij kids in **B** van respiratoir ...

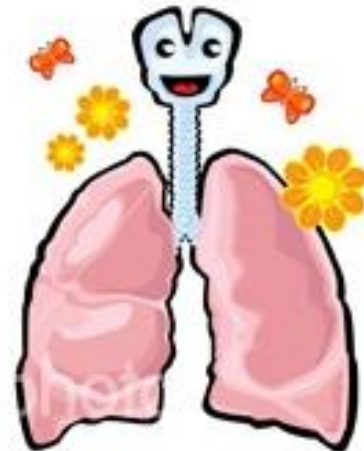
- Hoger metabolisme, O₂ verbruik en CO₂ prod.
- Meer compliante thoraxwand;
verhoudingsgewijs lagere FRC!!
- Meer type II fibers en sneller fatigue
- Belangrijke rol diafragma (>30%) vs.
diafragma vlakker en minder muscle



RESPIRATOIR falen

- Art. Hypoxemia ($\text{PaO}_2 < 60 \text{ mmHg}$)
+/-
- Art. Hypercapnia ($\text{PaCO}_2 > 50 \text{ mmHg}$)

- +/- tekenen van resp. distress...
Bv. gedaald BWZ: hypoventilatie en risico obstructed airway



Resp. falen... Ken je fysiologie?

- **pO₂**

 - ~ FiO₂

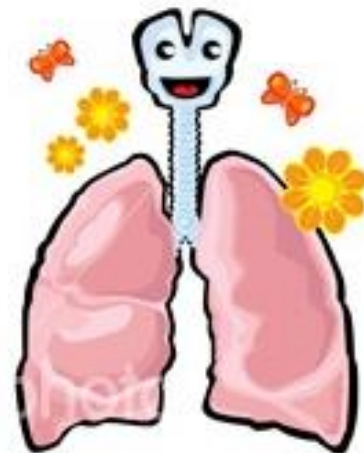
 - ~ VQ matching

 - ~ alveolocapp diffusie (PEEP, surfactant...)

- **pCO₂**

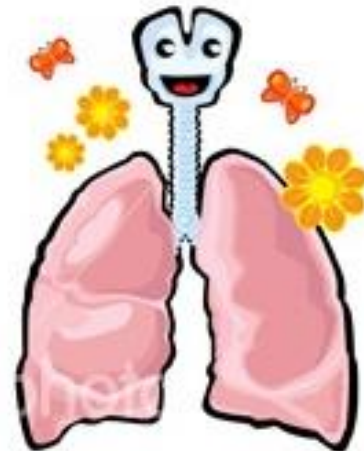
 - ~ AMV = TV * RR (normaal TV ~ 7ml/kg)

 - (~) VQ matching



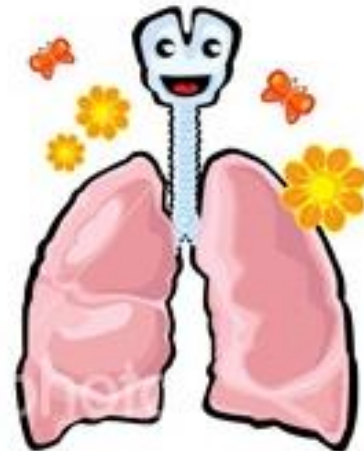
Respiratoir falen...

- **>> VQ mismatch**
 - vb. atelectase, pneumonie, ARDS...
 - Effect FiO_2 op pO_2 ~ shuntfractie, pCO_2 no tot \uparrow
- **< intra- of extracardiale shunt**
 - vb. AV malfo, uitgebreide atelectase, *LW obstructie*
 - Geen effect FiO_2 op pO_2 , pCO_2 \uparrow
- **Diffusiestoornis (alveolocapp. membraan)**
 - vb. ALO, ARDS...
 - Weinig impact pCO_2
- **Hypoventilatie**
 - vb. Neuromusc, diafragma, coma, obstructief II...
 - Zuivere hypoventilatie: pCO_2 omgekeerd ~ pO_2 , goed effect FiO_2



Tekenen van **distress**...

- Resp. rate (tachy = <1j: >40, 2-5j: >30, 5-12j: >25...)
- Work of Breathing: recessie –tirage – head bobbing – tripod positie...
- Bijgeluiden (grunting)
- Wijzigen bewustzijn
- Tachycardie
- Bleek tot **uiteindelijk** cyanose



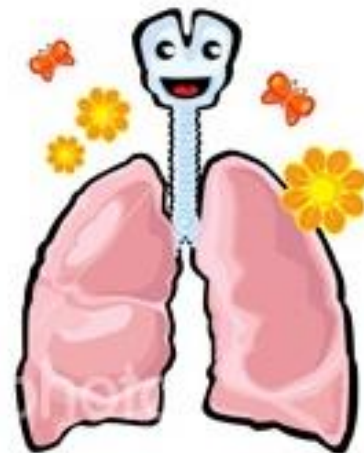
Respiratoir falen...

COMPENSATIE


- Tachypnoe – WOB
- Toename TV
- Grunting
- Tachycardie –
toename SVR
- (Pulm. Hypoxische VC)

DECOMPENSATIE

- Cyanose
- Hypercapnie
- Fatigue (minder effort)
- Stupor > coma
- Brady...



WHERE are we GOING?



'Where are we going?'

'I don't know. I thought you knew.'

'No, I don't know. Maybe he knows.'

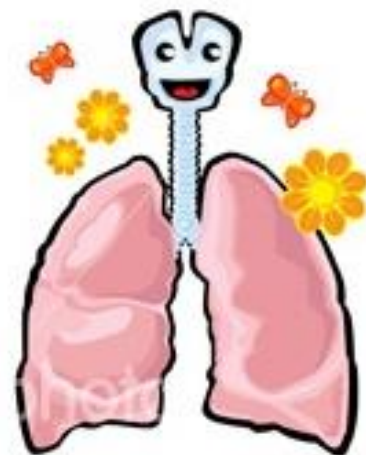
'No. He definitely doesn't know.'

PAUSE

'Maybe no-one knows.'

PAUSE

'oh well. I hope it's nice when we get there.'

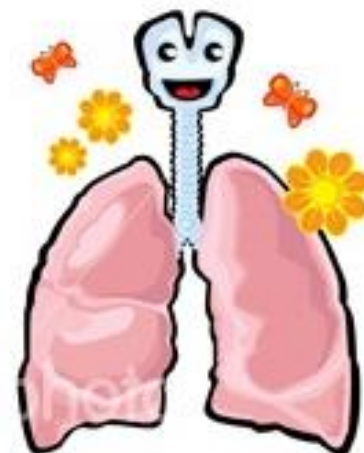


Liesje, 1j of 4j of 7j....

- **STAP 1: AIRWAY**

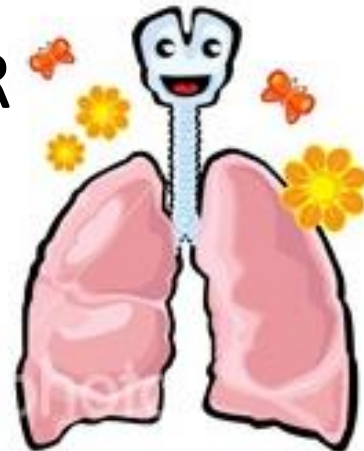
- Neutral to (hyper)extensie ‘sniffing’
- chin lift – jaw thrust
- Suctie!
- Oro / Nasopharyngeale luchtweg (size!!)
- [intubatie]
- (anticipated) Difficult airway management

- **Cervicale WZ**



CWZ !

- Immobilisatie in lijn...
- Onstabiele fractuur < 5% polytrauma;
2/3 init. geen uitval; D10: respiratoir / D5: CaV
- pijn midlijn cervicaal, uitval (rect. toucher...) vs.
Gedaald BWZ
- spiraalCT (+3D); Rx flexie/extensie; NMR
- SCIWORA
- ?? Mpred 30 mg/kg + 5.4 mg/kg/u

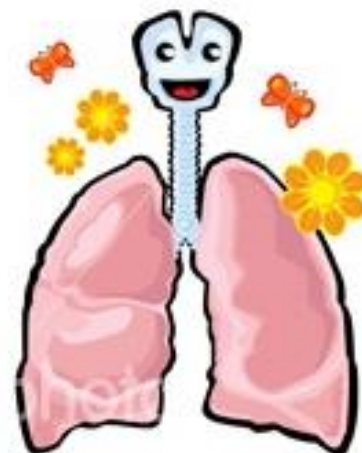


Liesje, 1j of 4j of 7j....

- **STAP 2: BREATHING**

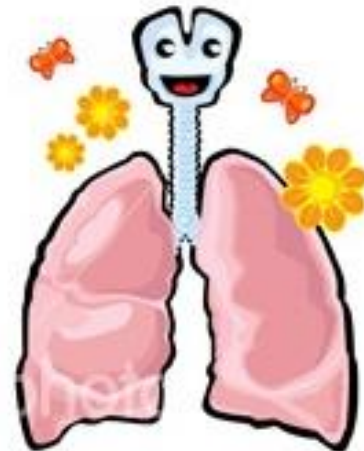
- FiO₂ (...)
- Masker-ballonventilatie(normoventilation)
- Intubatie

- Kunstmatige Ventilatie
- Niet-invasieve Ventilatie



INTUBATIE

**SEE ONE, DO ONE, TEACH ONE...
BUT NOT ON MY CHILDREN!!!**



INTUBATIE

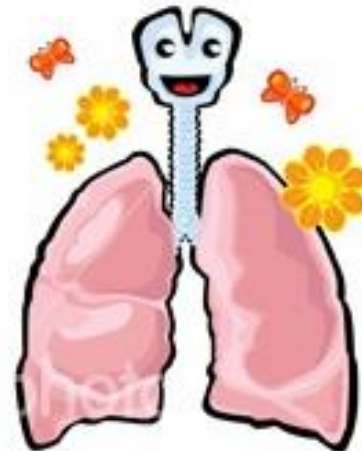


INDICATIES

- Failure to oxygenate or ventilate
- Fatigue
- Neuromuscular
- CaV failure (! Cardiac arrest)
- CNS failure

RISICO's

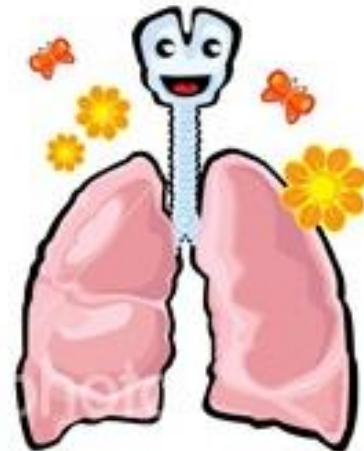
- Hypo/hyperV
- Hypoxia
- LW trauma
- Braken
- ICP stijging
- Vagaal
- Pneumoth.
- verplaatsen...

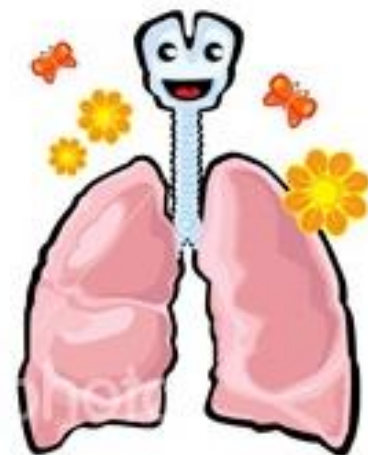


Do **not** continue things that do not work !!

- Can ventilate/oxyg: wait for help!
- Can't ventilate/ox: adjuncts – position.. – 2 person
- Still can't ventilate/ox: intubate
- Can't intubate: help – adequacy? - Rescue
- (Can't rescue: 'surgical' airway or similar)

- DOPES:.....

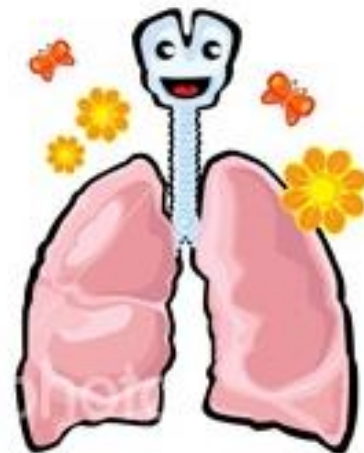




INTUBATIE materiaal

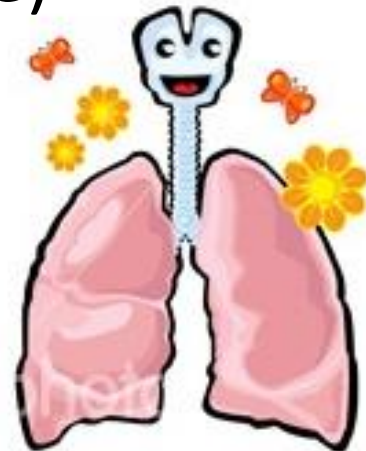
- O2 en BMV (correct masker); suctie; LW adjuncts; positie (rolletje)
- Tubemaat ($\text{age}/4 + 4$) (+ 1 maat groter en kleiner) & orale diepte ($\text{age}/2 + 12$) ; stylet (tip niet voorbij..)
- Laryngoscoop (recht vs curved blade); (McGill)
- Reanimatie en inductie medicatie
- Cuff of niet? (trachea trechter vs. low pressure cuffs...)
- Materiaal om te fixeren (Melbourne strapping)
- IV or IO access...
- 😊 stoeltje

- Unanticipated difficult airway (larynxmasker, bougie...)



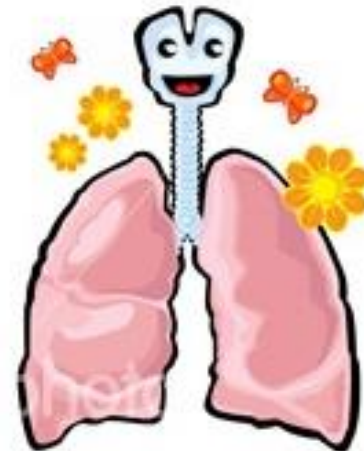
Rapid Sequence Intubatie

- Preoxygenatie 3' (FRC)
- Voorzover mogelijk spontaan AH
- Cricoid pressure?
- (atropine vs vagal)
(3' vooraf lidocaine vs ICP, bronchospasme)
- Fast (short) acting medicatie:
analgo-sedatie + spierrelaxatie
- 'Orale' Intubatie (30")



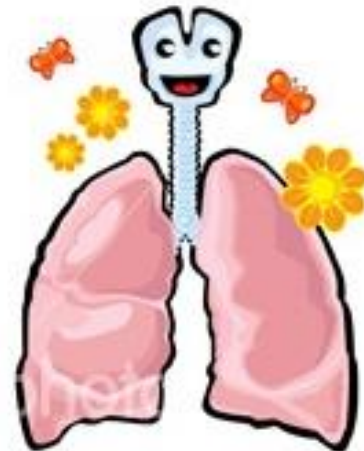
Rapid Sequence Intubatie

- Ethomidate: effective, HD stable, lowers ICP
 - risk of focal convulsions, myoclonics (R/ fentanyl)
 - Adrenal suppression after single dose (48h)
- Midazolam: variable effectiveness, HD impact
 - anti-epileptic ++
- Barbiturate: effective and fast, large HD impact, lowers ICP
- Propofol: effective and fast, large HD impact, lowers ICP
- Ketamine: effective and fast, even \uparrow MAP
 - Risk of ICP \uparrow low if associated with e.g. Benzo
- Succinylcholine: very fast, 6' recovery
 - Contraindications!!
 - ICP \uparrow (R/ DEFASCIC dose of non depol curare)
- Rocuronium: HD effective, onset 30", 45-60' recovery
 - Bridion^R



The job is not done ...

- Bevestig positie: klin., RX, etCO₂, Ausc, Sat...
- Inadequate verbetering na intubatie: excess. lek, inad TV of PEEP; air trap; ventilator systeem failure of inad. O₂ flow bron; DOPES!
- Plotse deterioratie: DOPES!



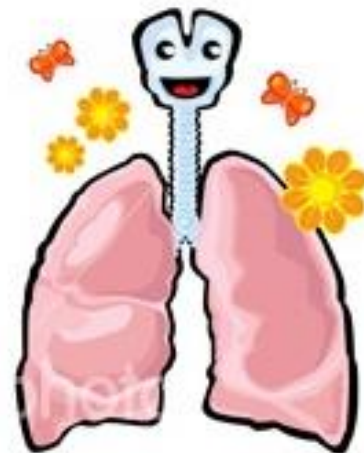
The job is not done....

- **STAP 3: Circulation**

- Hart-longinteractie (hyperinflatie, ventilator...);
inductiemedicatie en verdere sedatie
- Catecholamine / CO

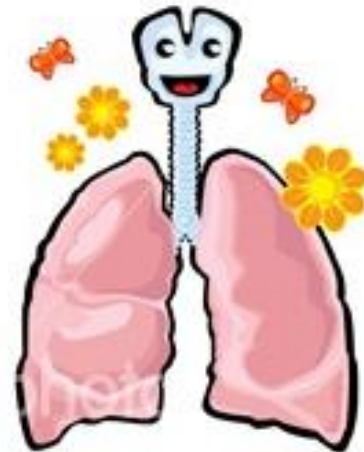
- **STAP 4: disease-specific**

- Bronchodilat. (aerosol-spacer/IV); Adrenaline aerosol
- Minimal Touch; Kine
- Steroiden ; Antibiotica
- Chirurgie.....



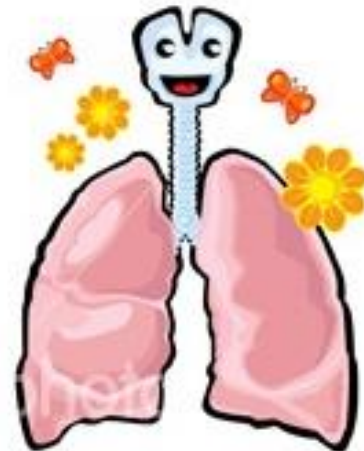
(UN)ANTICIPATED DIFFICULT AIRWAY / INTUBATION

- Inspecteer.... Wees aandachtig..
- Have a **backup plan** (for your backup plan 😊)
- Denk eraan igv
 - Facial trauma
 - Mouth opening problems
 - Obesity
 - Obstructions
 - Decompensated respiratory failure
 - Congenital abn. airway: Pierre Robin, Treacher-Collins, Down, MPS, Cri Du Chat...



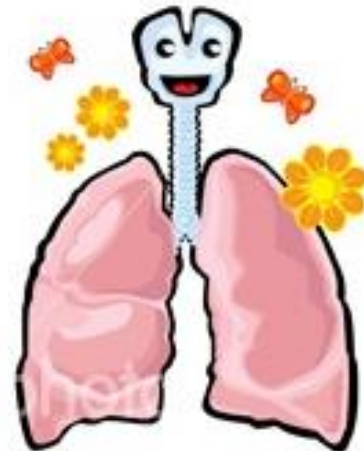
(UN)ANTICIPATED DIFFICULT AIRWAY

- Alternatives to RSI
- Alternatives to endotracheal intubation
- Alternatives to direct laryngoscopy



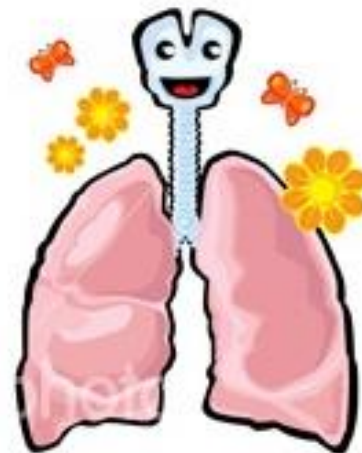
Alternatives to RSI

- Inhalation induction: spontaneous ventilation preserved... (risico larynxspasme, minder goede relax.)
- Bridion
- Topical Lidocainespray 4% (?)



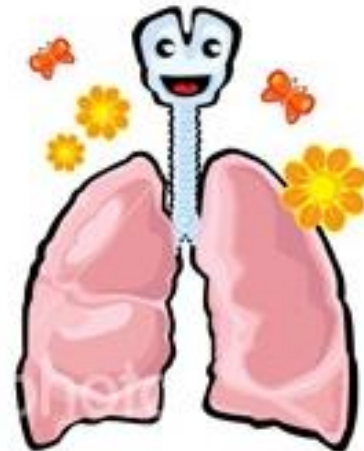
Aids for RSI

- Gum elastic Bougie (/ ETT exchanger)
 - C-spine neutral
 - risk of airway trauma
 - 2 person!
- Video Laryngoscopie
 - Mc Grath, storz GlideScope
 - Ped sizes available
 - Less trauma, effective
 - > time (16"); secretions...
 - “under study”



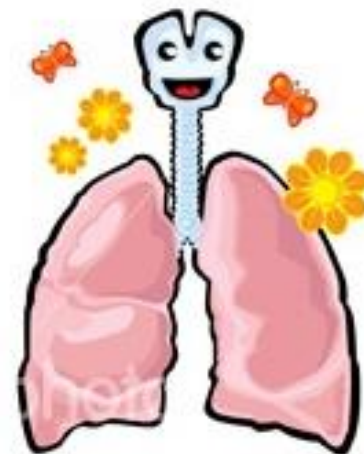
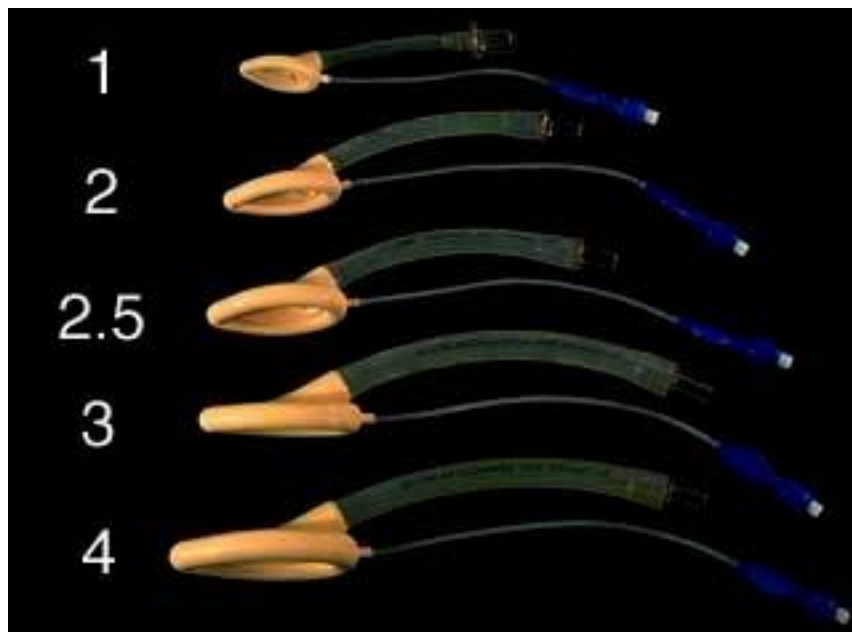
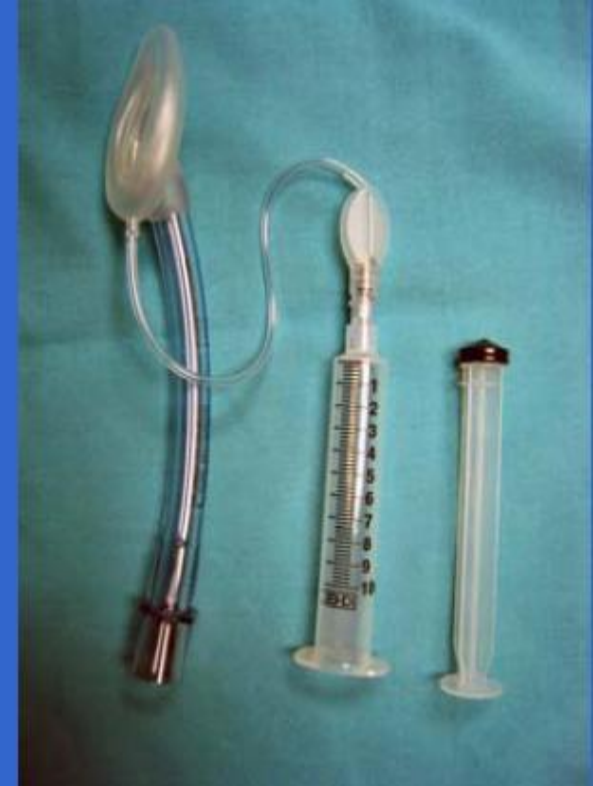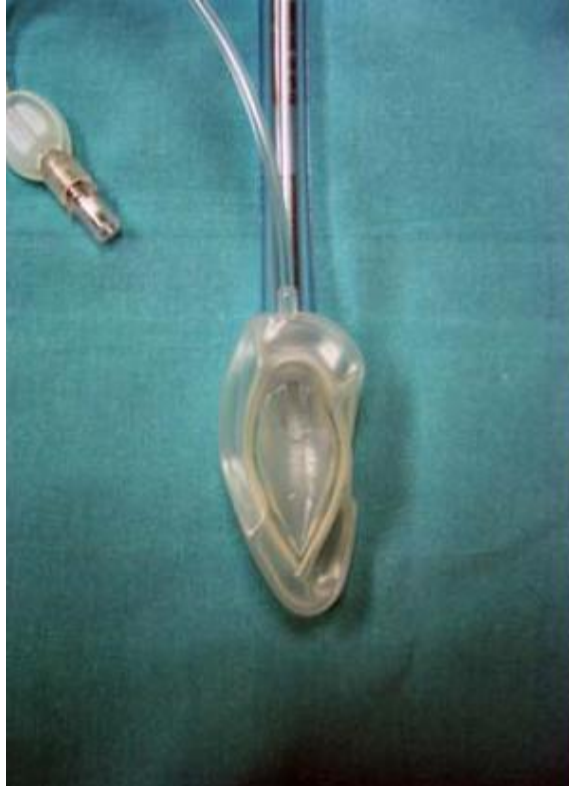Alternatives to Endotracheal intub.

- Mask airway + oral/nasal airway
 - Minimal invasive; uses hands
 - does not protect from aspir.
- Laryngeal Mask LMA
 - Less invasive, hands free, not difficult
 - Controlled or spontaneous V
 - Evt. conduit for assisted intub...
 - does not protect from aspir.
 - Soft tissue trauma
 - Easily dislodged



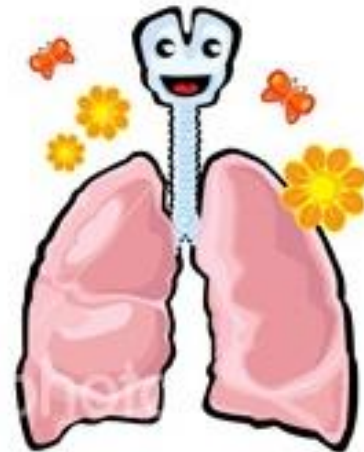
LMA

GW	size	ETT
<5	1	≤ 3.5
5-10	1.5	≤ 4
10-20	2	≤ 4.5
20-30	2.5	≤ 5
>30	3	≤ 6



LMA

- Plaatsing: size, lubricate, partially inflated, no wrinkles!
- Alternatieven:
 - initieel insertie 180° gedraaid
 - Corkscrew
 - 90° gedraaid langs zijkant mond
 - Steady downward pressure
- Assisted intubation: blind (bougie-tube exchanger), (fastTrach), fiberoptic



Alternatives to direct laryngoscopy

- Blind nasal intubation
 - Lukt niet in (kleine) kinderen
- Light wand
 - beperkt ped. ervaring; oro- & nasophar.
 - ETT erover, GEEN cricoid druk
- CombiTube
 - Geen pediatrische maten
 - Eenvoudig maar bv. geen suctie, oesof. trauma...
 - Knutselen ...
- Fiberoptic intubatie

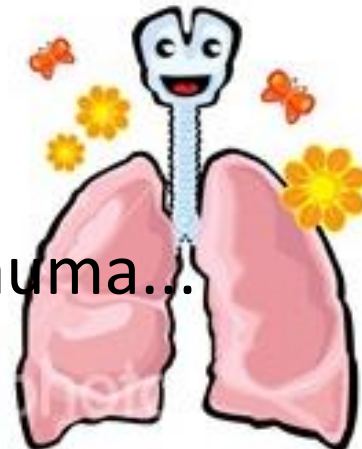


Figure 2

[Bronchoscopy via a Redesigned Combitube\(TM\) in the Esophageal Position: A Clinical Evaluation](#)

Krafft, Peter; Roggla, Martin; Fridrich, Peter; Locker, Gottfried J.; Frass, Michael; Benumof, Jonathan L.

Anesthesiology. 86(5):1041-1045, May 1997.

doi:

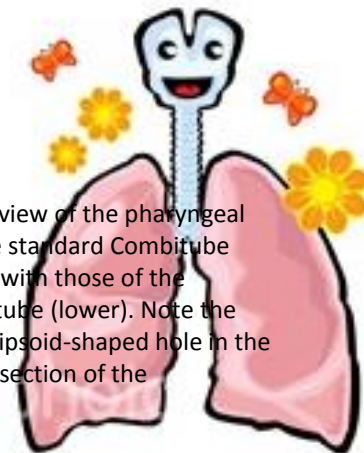
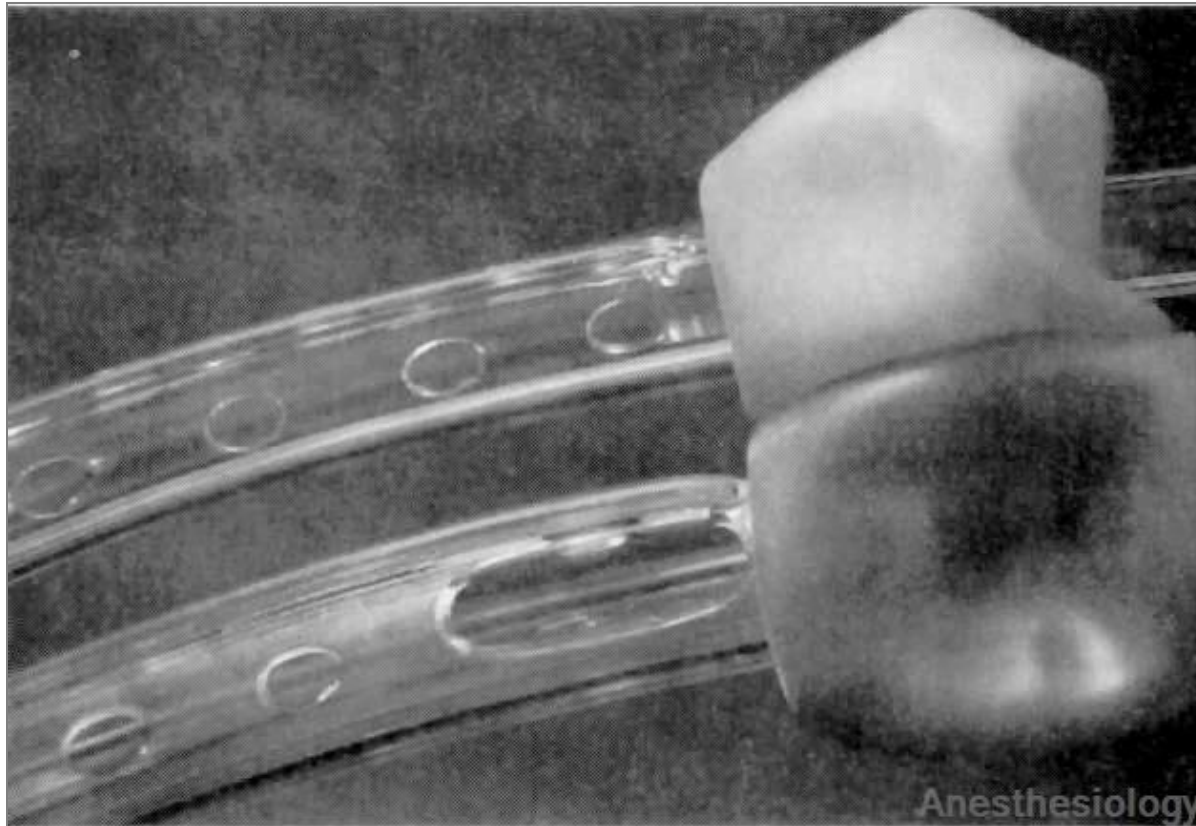
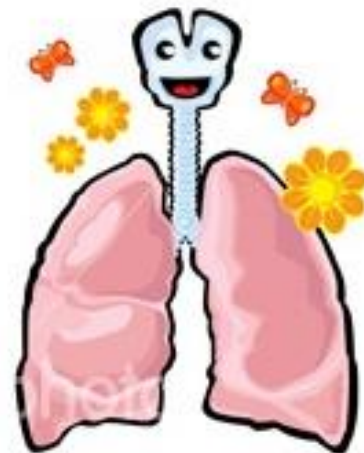


Figure 2. Close-up view of the pharyngeal perforations of the standard Combitube (upper) compared with those of the redesigned Combitube (lower). Note the single large and ellipsoid-shaped hole in the anterior, proximal section of the redesigned model.

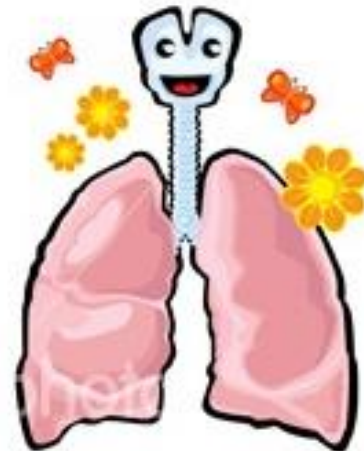
Fiberoptic intubatie

- Niet zo easy: small size, anatomic diff, smaller FRC...
- Evt via LMA...
- Anesth maar spontane AH...



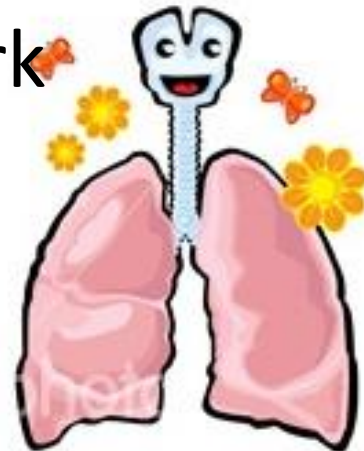
Unable to RESCUE?

- Retrograde wire (Cook kit)
 - Techn moeilijk (smal en moeilijk te local cricothyroid membr.)
 - Ophalen draad via suctie...
- Tracheostomie: chirurgisch; bedside (volw)
 - Risico vasc, stricturen....
- Cricothyroidotomie:
 - Technisch moeilijk en idem risico's (+ pneu, fausse route): laatste redmiddel
 - grote IV, 2CC spuit, Tubeconnect 7.0, ballon – 100%O₂
 - JET V; flowO₂ lijn met 3 weg kraan (1L/y max 6)
 - Commerciele pediatrische sets...

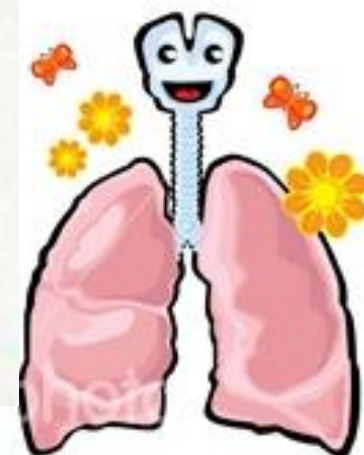

DUS...

- De aanpak van elke urgentie begint bij **ABCD**
- Fysiologische en anatomische verschillen kind
- Intubatie.. Gevaarlijk maar soms noodzaak
- Wees alert voor de (un)anticipated difficult AW en voorzie een **backup** plan
- Do not continue things that do not work



THE END



References

- Gausche M, et al. Effect of out-of-hospital pediatric endotracheal intubation on survival and neurologic outcome. *JAMA*. 2000. 283(6): 783-790.
- Gilligan BP, et al. Pediatric Resuscitation. In *Rosen's Emergency Medicine: Concepts and Clinical Practice, 6th Ed*. Mosby, 2006.
- Biarent, et al (Ed). *EPLS manual*. Second edition, ERC, 2006.
- Lee BS, et al. Pediatric airway management. *Clin Ped Emerg Med*. 2001. 2(2): 91-106.
- Luten RC. The pediatric patient. In *Manual of Emergency Airway Management, 2nd Ed*. Lippincott, 2004.
- Tobias JD. Airway management for pediatric emergencies. *Pediatric Annals*. 1996; 25:317-28
- Kundra P, Krishnan S. Airway management in children. *Indian J Anesth*. 2005; 49:300-307
- Nolan JP, Wilson ME: Orotracheal intubation in patients with potential cervical spine injuries. An indication for the gum elastic bougie. *Anaesthesia* 1993;48:630-3
- Van Zundert AA, Maassen RL, Hermans B, Lee RA. Videolaryngoscopy--making intubation more successful. *Acta Anaesthesiol Belg*. 2008;59(3):177-8.

